

PD DR. MED. NILS KUCHER, FESC
Swiss Cardiovascular Center, Switzerland

Treatment of Bilateral, Submassive Pulmonary Embolism with Acoustic Pulse Thrombolysis™ Treatment

Patient History

A 68yo previously healthy female with history of hypertension and one episode of atrial fibrillation 12 months ago presented with dyspnea and left-sided chest pain after a few days of long distance train travel. No personal or family history of VTE and no other VTE risk factors present.

- The patient had no syncope and was hemodynamically stable on admission with preserved systemic blood pressure
- CT angiography confirmed bilateral pulmonary embolism in the main pulmonary arteries (PA) and segmental arteries of both upper and lower lobes and a pulmonary infarct of a left upper lobe segmental branch
- The brain neuro-peptide was elevated and troponin test was negative
- Echocardiography demonstrated RV dilation and dysfunction with an estimated PA pressure by echo (via tricuspid regurgitant velocity) of 70 mmHg

Treatment

The patient was initially managed with anticoagulation alone (unfractionated heparin (UFH) infusion at therapeutic levels. On the second hospital day, despite anticoagulation the patient developed worsening dyspnea and required 12 liters per minute of oxygen via mask to maintain adequate oxygenation. Blood pressure remained stable.

- Repeat CT angiography confirmed unchanged bilateral PE and RV dilation with an RV/LV ratio of 1.1
- Selective pulmonary angiography showed obstructive thrombus in the right main PA and impaired flow in the right upper and lower lobe PA and non-obstructive thrombus in the left lower lobe PA, but obstructive thrombus in the two left upper lobe PA branches. Measured PA pressure was 72/20/36 mmHg.
- Access was obtained via the right superficial femoral vein. The obstructive thrombus in the right PA was crossed with a Terumo 0.035 soft curved-tip wire. Selective injection distal to the thrombus confirmed intraluminal wire position in a lower lobe PA branch. A 30 cm treatment zone EKOS® device was placed in the right PA across the occlusive thrombus.
- rt-PA infused at 2 mg/hour for 5 hours, then reduced to 1 mg/h for 10 hours (total 20 mg rt-PA in 15 hours). UFH was given at a dose of 1000 U/h through the sideport of the femoral sheath and adjusted according to the thrombin time.

Results

At 15 hours, follow-up selective pulmonary angiography revealed open main and lobar pulmonary arteries on both sides with residual non-obstructive thrombus in both lower lobe segmental branches. Invasive PA pressure was 40/12/20 mmHg. The patient's respiratory symptoms improved substantially with no need for supplementary oxygen.

"Nearly complete resolution of thrombus within 15 hours of therapy resulted in rapid recovery of hemodynamics in this very symptomatic patient."

- Nils Kucher, MD

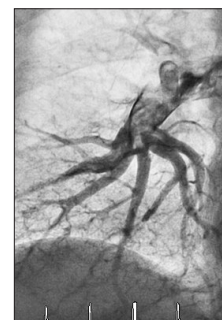


Figure 1 - Thrombus in right main pulmonary artery.

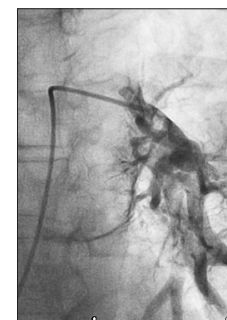

Figure 2 - Thrombus in the left main and lower lobe pulmonary arteries.

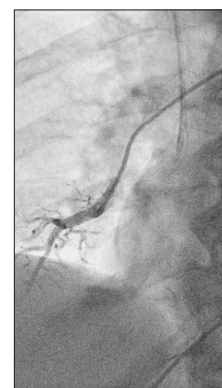

Figure 3 - Selective angiography of right lower lobe pulmonary artery confirmed intraluminal wire position in a lower lobe PA branch.

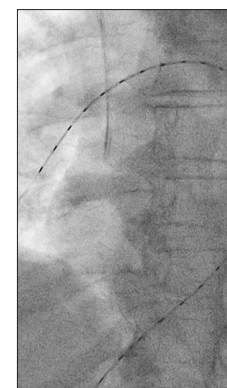


Figure 4 - EKOS® device in place - 30 cm treatment zone

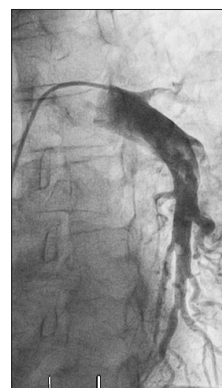

Figure 5

Post therapy angiography demonstrated significant thrombus resolution and restoration of flow in both main pulmonary arteries with non-obstructive residual thrombus in the lower lobe arteries.

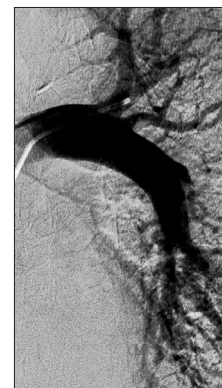

Figure 6

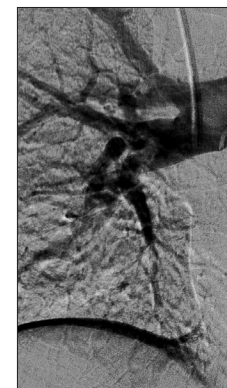


Figure 7



FDA CLEARED INDICATIONS: The EkoSonic® Endovascular System is indicated for the ultrasound facilitated, controlled and selective infusion of physician-specified fluids, including thrombolytics, into the vasculature for the treatment of pulmonary embolism; the controlled and selective infusion of physician-specified fluids, including thrombolytics, into the peripheral vasculature; and the infusion of solutions into the pulmonary arteries. Instructions for Use, including warnings, precautions, potential complications, and contraindications can be found at www.ekoscorp.com. Caution: Federal (USA) law restricts these devices to sale by or on the order of a physician. EKOS® and EkoSonic® are registered trademarks of EKOS Corporation, a BTG International group company. Acoustic Pulse Thrombolysis is a trademark of EKOS Corporation. BTG and the BTG roundel logo are registered trademarks of BTG International Ltd. © 2015 EKOS Corporation • US-EKO-2015-0484

EKOS CORPORATION
11911 N Creek Pkwy S.
Bothell, WA 98011