

DR. TOD ENGELHARDT, MD

East Jefferson Hospital, New Orleans, LA

Extensive DVT Resolution using EKOS® System

Patient History

71-year-old female with massive swelling of left lower extremity and extensive DVT. Left total knee replacement two weeks prior.

- Venography in prone position confirmed the presence of occlusive thrombus in the entire left femoral and iliac veins, extending into the inferior vena cava

Treatment

50cm (135cm working length) EKOS® Device

- Access was obtained through left popliteal vein
- Treatment zone covered the left femoral and iliac veins and extended into the inferior vena cava
- 4 mg bolus of tPA
- rt-PA was infused through the EKOS® Device at 1mg/hr for 14 hours

Midpoint Results

After 14 hours of treatment and 18mg rt-PA:

- Venography showed resistant thrombus in left common femoral vein and persistent obstruction at iliac caval junction preventing flow into inferior vena cava
- Mechanical thrombectomy followed by balloon dilation in the common femoral resulted in improved flow, but with some persistent thrombus
- Three balloon dilations at the common iliac vein caval junction restored partial flow, but still evidence of thrombus
- A 6cm EKOS® catheter was then placed at common iliac vein caval junction and treatment restarted in the area of persistent stenosis and thrombus
- rt-PA infused at a rate of 1mg/hr for an additional 24 hours

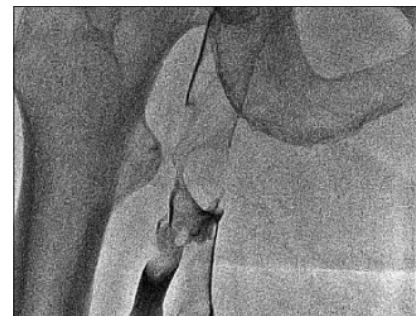Final Results

After an additional 24 hours of treatment and 24mg of rt-PA:

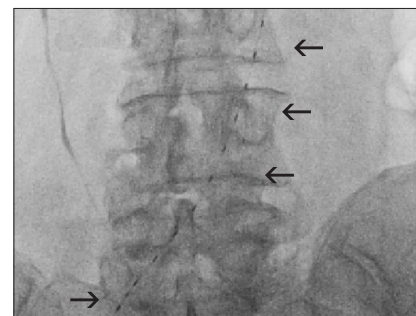
- No clot remaining in femoral vein
- Brisk flow restored into inferior vena cava, with some residual stenosis in iliac vein
- Inferior vena cava filter placed via right femoral vein approach

“With the help of Acoustic Pulse Thrombolysis™ treatment, massive lower extremity swelling with complete occlusion of IVC can be safely treated. This concurs with the excellent results I continue to see in the treatment of venous thrombosis disease with EKOS®.” Tod Engelhardt, MD

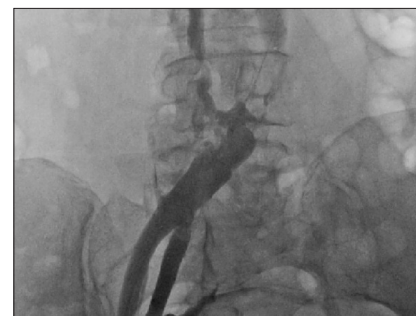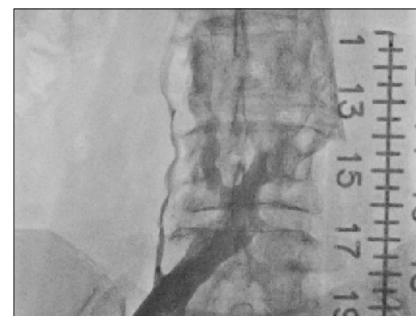Thrombus in left iliac vein and IVC



EKOS® catheter placed through left femoral vein up into IVC



Flow restored in femoral vein, iliac vein, and IVC



FDA CLEARED INDICATIONS: The EkoSonic® Endovascular System is indicated for the ultrasound facilitated, controlled and selective infusion of physician-specified fluids, including thrombolytics, into the vasculature for the treatment of pulmonary embolism; the controlled and selective infusion of physician-specified fluids, including thrombolytics, into the peripheral vasculature; and the infusion of solutions into the pulmonary arteries. Instructions for Use, including warnings, precautions, potential complications, and contraindications can be found at www.ekoscorp.com. Caution: Federal (USA) law restricts these devices to sale by or on the order of a physician. EKOS® and EkoSonic® are registered trademarks of EKOS Corporation, a BTG International group company. Acoustic Pulse Thrombolysis is a trademark of EKOS Corporation. Acoustic Pulse Thrombolysis is a minimally invasive system for dissolving thrombus. BTG and the BTG roundel logo are registered trademarks of BTG International Ltd. © 2014 EKOS Corporation • US-EKO-2014-1528

EKOS CORPORATION
11911 N Creek Pkwy S.
Bothell, WA 98011